
بسم الله الرحمن الرحيم

Celiac chalenges

Dr shaahin shahbazi

Gastroenterologist

Associated professor

Celiac disease is a small bowel disorder characterized by :

-mucosal inflammation

- villous atrophy
- crypt hyperplasia

which occur upon exposure to dietary gluten and demonstrate improvement after withdrawal of gluten from the diet.

Celiac disease should be differentiated from nonceliac gluten sensitivity in order to identify the risk for nutritional deficiency and complications of celiac disease and to determine the necessary degree and duration of adherence to a gluten-free diet.

WHO SHOULD BE TESTED

- asymptomatic first-degree relatives
- chronic or recurrent diarrhea or constipation
- malabsorption
- unexpected weight loss
- abdominal pain
- distension, or bloating.
- symptoms suggestive of irritable bowel syndrome or refractory lactose intolerance.

- persistent elevation in serum aminotransferases
- dermatitis herpetiformis
- Fatigue
- recurrent headaches
- recurrent fetal loss
- low birthweight offspring
- reduced fertility
- persistent aphthous stomatitis
- dental enamel hypoplasia
- metabolic bone disease and premature osteoporosis
- idiopathic peripheral neuropathy, or nonhereditary cerebellar ataxia

Risk factors that place an individual at moderate to high risk for celiac disease include:

- First- and second-degree relative with confirmed celiac disease
- Type 1 diabetes
- Autoimmune thyroiditis
- Down and Turner syndromes
- Pulmonary hemosiderosis

- The diagnostic approach is based on the risk for celiac disease and GI or Extra –GI manifestations and whether the patient is on a gluten-containing diet.
- All testing for celiac disease should ideally be performed while patients are on a gluten-containing diet.

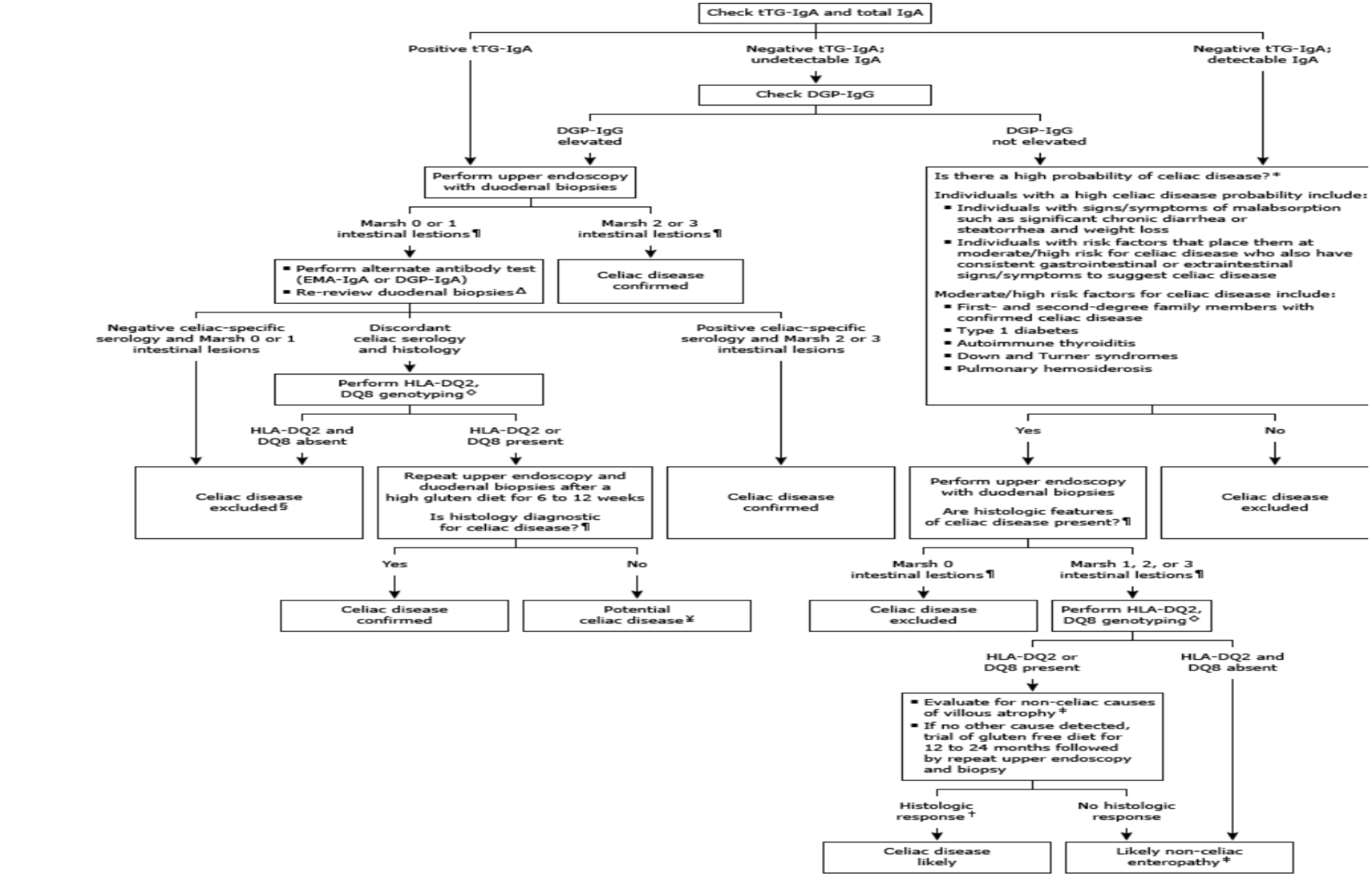
Check tTG-IgA and total IgA
Positive tTG-IgA
Negative tTG-IgA; undetectable IgA
Negative tTG-IgA; detectable IgA
Check DGP-IgG
DGP-IgG elevated
DGP-IgG not elevated
Perform upper endoscopy with duodenal biopsies
Marsh 0 or 1 intestinal lestions ¶
Marsh 2 or 3 intestinal lestions ¶
▪ Perform alternate antibody test (EMA-IgA or DGP-IgA)
▪ Re-review duodenal biopsies Δ
Celiac disease confirmed
Negative celiac-specific serology and Marsh 0 or 1 intestinal lesions
Discordant celiac serology and histology
Positive celiac-specific serology and Marsh 2 or 3 intestinal lesions
Perform HLA-DQ2, DQ8 genotyping ◇
HLA-DQ2 and DQ8 absent
HLA-DQ2 or DQ8 present
Celiac disease excluded §
Repeat upper endoscopy and duodenal biopsies after a high gluten diet for 6 to 12 weeks
Is histology diagnostic for celiac disease? ¶
Celiac disease confirmed
Yes
No
Celiac disease confirmed
Potential celiac disease ¥
Is there a high probability of celiac disease? *
Individuals with a high celiac disease probability include:
▪ Individuals with signs/symptoms of malabsorption such as significant chronic diarrhea or steatorrhea and weight loss
▪ Individuals with risk factors that place them at moderate/high risk for celiac disease who also have consistent gastrointestinal or extraintestinal signs/symptoms to suggest celiac disease
Moderate/high risk factors for celiac disease include:
▪ First- and second-degree family members with confirmed celiac disease
▪ Type 1 diabetes
▪ Autoimmune thyroiditis
▪ Down and Turner syndromes
▪ Pulmonary hemosiderosis
Yes
No
Perform upper endoscopy with duodenal biopsies
Are histologic features of celiac disease present? ¶
Celiac disease excluded
Marsh 0 intestinal lestions ¶
Marsh 1, 2, or 3 intestinal lestions ¶
Celiac disease excluded
Perform HLA-DQ2, DQ8 genotyping ◇
HLA-DQ2 or DQ8 present
HLA-DQ2 and DQ8 absent
▪ Evaluate for non-celiac causes of villous atrophy ‡
▪ If no other cause detected, trial of gluten free diet for 12 to 24 months followed by repeat upper endoscopy and biopsy
Histologic response †
No histologic response
Celiac disease likely
Likely non-celiac enteropathy ‡

Serologic evaluation

- Tissue transglutaminase (tTG)-IgA antibody is the single preferred test for detection of celiac disease in adults.
- In addition, we concurrently measure total IgA levels.
- In patients with IgA deficiency, we perform IgG-based testing with deamidated gliadin peptide (DGP)-IgG

The diagnostic performance of serologic tests for celiac disease are influenced by the following factors:

- wide variations in test sensitivity and specificity among different laboratories .
- It is therefore important to know the sensitivity and specificity of the assay as performed by the testing laboratory before determining the clinical significance of a particular test result

Severity of celiac disease

- – In addition to laboratory variation, the sensitivity of celiac tests may depend upon the severity of celiac disease.
- The sensitivity of EMA-IgA varied from 100 percent in patients with total villous atrophy to only 31 percent in those with partial villous atrophy.

Dietary factores:

A weakly positive serologic test for celiac disease may become negative within weeks of adherence to a gluten-free diet.

Patient age :

tTG-IgA and EMA-IgA may be falsely negative in children under two years.

IgA deficiency :

- Undetectable IgA levels but not partial immunoglobulin A deficiency (low but detectable serum IgA) decreases the sensitivity of TTG-IgA

Negative celiac serologies in patients with celiac disease

- IgA deficiency – tTG-IgA serology will be falsely negative in untreated celiac disease in patients with IgA deficiency, common variable immunodeficiency, or the use of an immunosuppressant.

- Low gluten/gluten-free diet

- False negative –False-negative serology is more common in patients with mild disease on histology.

Endoscopic features and biopsy technique

- Endoscopic features of celiac disease include atrophic appearing mucosa with loss of folds, visible fissures, nodularity, scalloping, and prominent submucosal vascularity .
- However, endoscopic features suggestive of celiac disease have low sensitivity (59 to 94 percent). The reported specificity ranges from 92 to 100 percent and these findings may be seen with other disorders such as giardiasis, autoimmune enteropathy, and HIV infection

- Multiple biopsies of the duodenum (one or two from bulb and four from distal duodenum) are necessary for diagnosis of celiac disease.
- Bulb biopsies, if taken, should be clearly labeled as such to help ensure that the pathologist takes into account the different mucosal architecture of the bulb to avoid false-positive reports of villous atrophy.

Causes of small intestinal villous atrophy other than celiac disease

Small intestinal bacterial overgrowth
Crohn disease
Cow's milk or soy protein intolerance (children)
Eosinophilic gastroenteritis
Giardiasis
Intestinal lymphoma
Peptic duodenitis
Post-gastroenteritis
Tropical sprue
Zollinger-Ellison syndrome
Common variable immunodeficiency
Autoimmune enteropathy
Other immunodeficiency states (usually apparent clinically, eg, AIDS enteropathy, hypogammaglobulinemic sprue)
Medications (eg, olmesartan, NSAIDs)
Whipple disease
Malnutrition
Intestinal tuberculosis
Graft-versus-host disease

Discordant serology and small bowel biopsy

False-positive tTG

-usually low titer (typically less than twice the upper limit of normal).

-during or after a febrile illness

False-negative biopsy results

-patchy distribution or initially be confined to the duodenal bulb

-The intestinal biopsy should be reviewed by a pathologist familiar with celiac disease to look for subtle abnormalities of celiac disease.

If serology and histology remain discordant, we perform HLA-DQ2/DQ8 typing (algorithm 1).

- HLADQ2/DQ8 is negative, celiac disease is excluded
- If HLADQ2/DQ8 is positive, the patient can be placed on a high-gluten diet (>10 grams per day, equivalent of at least four slices of gluten containing bread per day) and, after 6 to 12 weeks, additional biopsies obtained from multiple sites in the mid and distal duodenum since celiac disease enteropathy can be patchy and missed due to sampling error. The finding of Marsh type 2 or 3 lesions on histology in a patient with positive celiac serology is diagnostic of celiac disease (figure 1). (See 'Positive serology and diagnostic small bowel biopsy' above.)

- Patients with positive celiac-specific serologies in the absence of crypt hyperplasia or villous atrophy (Marsh 0 or Marsh 1) are considered to have potential celiac disease .
- Symptomatic patients with potential celiac disease are likely to benefit from treatment with a gluten-free diet.
- Asymptomatic patients can remain on a normal diet unless clinical features of celiac disease develop

Negative serology and abnormal small bowel biopsy

- perform HLA-DQ2/DQ8 genotyping.
- If haplotypes HLA-DQ2 or DQ8 are present, we recommend a gluten-free diet for 12 to 24 months and monitor the clinical response. We also perform a repeat upper endoscopy with biopsies after 12 to 24 months of a gluten-free diet to confirm mucosal healing.
- Patients with a histologic response are likely to have sero-negative celiac disease. Individuals without a histologic response likely have non-celiac villous atrophy

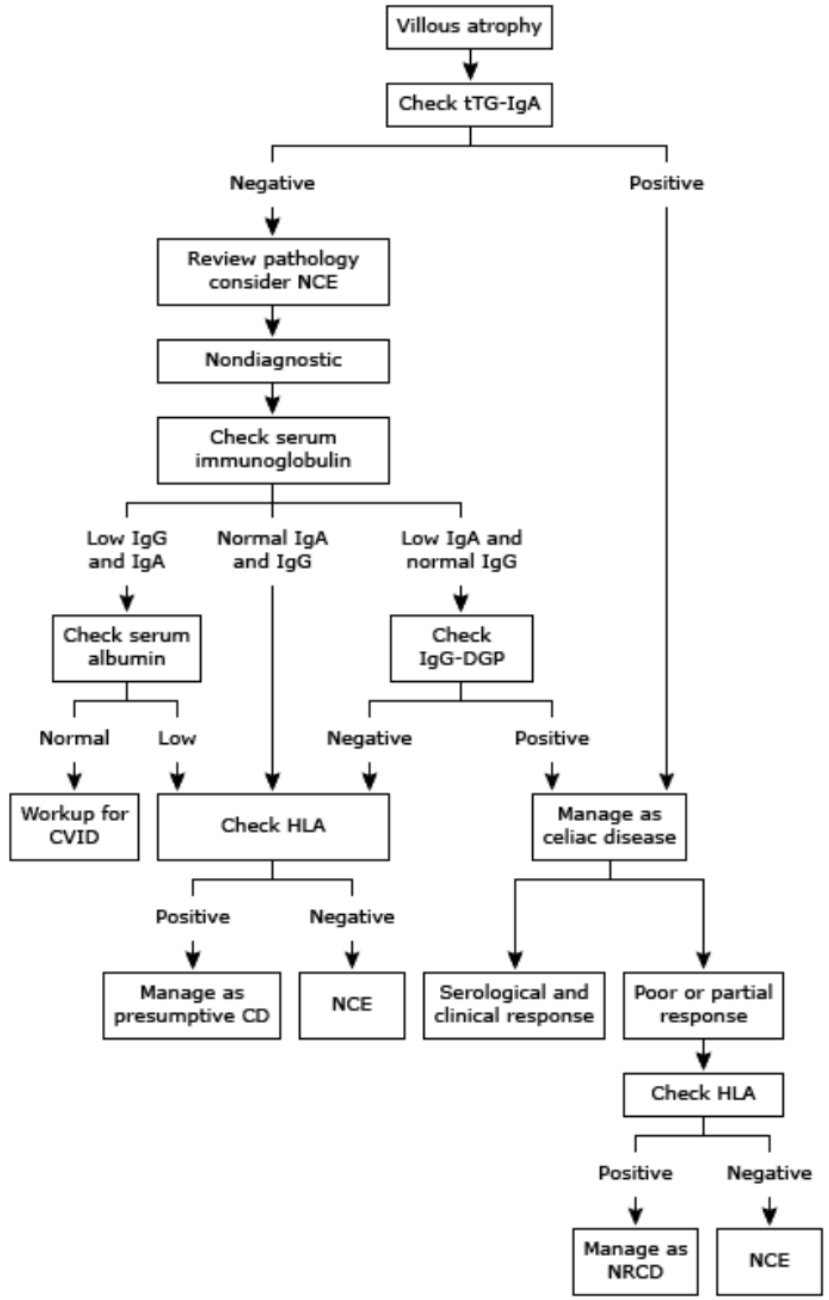
Villous atrophy
Check tTG-IgA
Negative
Positive
Review pathology consider NCE
Nondiagnostic
Check serum immunoglobulin
Low IgG and IgA
Normal IgA and IgG
Low IgA and normal IgG
Check serum albumin
Check IgG-DGP
Normal
Low
Negative
Positive
Workup for CVID
Check HLA
Manage as celiac disease
Positive
Negative
Manage as presumptive CD
NCE
Serological and clinical response
Poor or partial response
Check HLA
Positive
Negative
Manage as NRCD
NCE

HLA testing in selected patients

- has a negative predictive value of greater than 99 percent, but positive predictive value is only around 12 percent because these haplotypes are common in the general population

Hence, HLA testing is useful only in ruling out celiac disease:

●Patients with discordant celiac-specific serology and histology (see 'Discordant serology and small bowel biopsy' above).

●Patients who refuse upper endoscopy

●Evaluation of patients on a gluten-free diet with negative baseline serologies

●Patients with suspicion of refractory celiac disease where the original diagnosis of celiac disease remains in question

●most commonly used in at-risk children to obviate the need for periodic serology testing.

Dermatitis herpetiformis

- In patients with biopsy-proven dermatitis herpetiformis, the diagnosis can be established by serology without a small bowel biopsy.

unwilling or unable to undergo upper GI endoscopy

Symptomatic adults who are unwilling or unable to undergo upper GI endoscopy but have a high-level tTG IgA (>10-fold elevation above the upper limit of normal) with a positive endomysial antibody (EMA) in a second blood sample can be diagnosed as likely celiac disease

Patients on a gluten-free diet

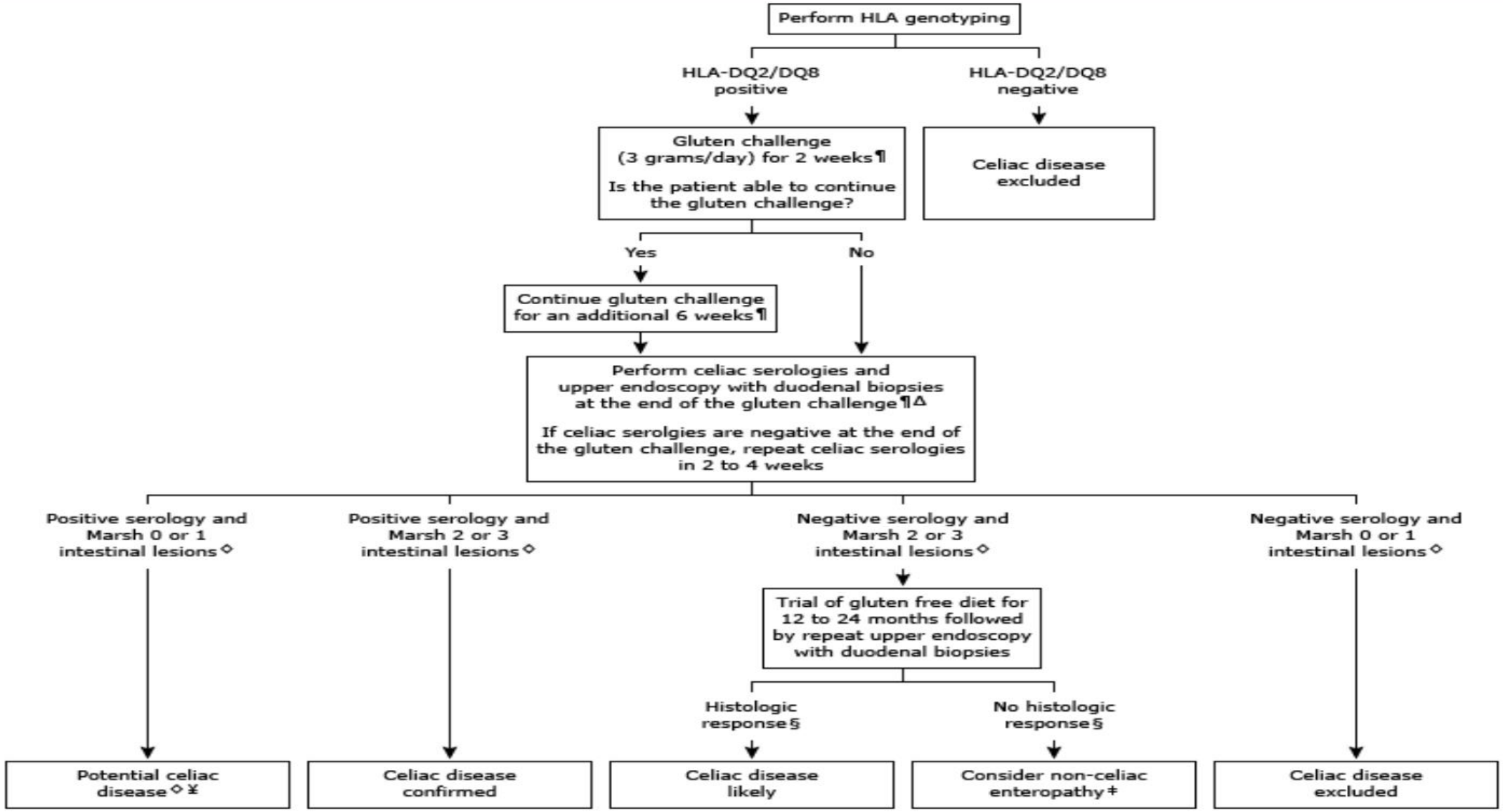

Patients unable/unwilling to undergo upper endoscopy

- — Symptomatic adults who are unwilling or unable to undergo upper GI endoscopy but have a high-level TTG IgA (>10-fold elevation above the upper limit of normal) with a positive endomysial antibody (EMA) in a second blood sample can be diagnosed as likely celiac disease

- In patients without a high-level tTG IgA, we perform HLA testing. Absence of alleles encoding DQ2 or DQ8 excludes celiac disease. In patients who are DQ2- or DQ8-positive and have positive celiac serologies, a video capsule endoscopy (VCE) may reveal visible features of celiac disease in the small intestine.

سپاس از توجه شما